

# Groove Patterns of Ablation for Fractional Skin Resurfacing: Clinical Results and Applications

Sean Doherty, Brooke Seckel, Christine Dierickx\*, and E. Victor Ross\*  
Boston Plastic Surgery Associates, Concord, MA, Laser Clinic Boom, Belgium\*,  
Scripps Clinic Carmel Valley, San Diego, CA\*

## Objective:

We report findings on a novel fractional skin resurfacing technology which uses a groove pattern of injury as opposed to the column pattern delivered with “traditional” fractional beam resurfacing.

## Conclusions:

This novel fractional resurfacing technology resulted in a 2.2 Fitzpatrick Wrinkle Scale (FWS) improvement in wrinkles, which is 38-50% better than the 1.4-1.6 FWS improvements reported for other fractional ablative treatments (per three month blinded-review). These data, along with additional outcomes such as improved dyspigmentation and minimal downtime and side effects, support our conclusion that the Groove™ Optic (Palomar Medical Technologies, Inc., Burlington, MA) enables a significant improvement in the ratio of clinical efficacy to side effects and downtime.

## Introduction:

Improving clinical efficacy while minimizing or eliminating downtime and long-lasting side effects are the goals of fractional ablative skin resurfacing treatments. However, while current fractional ablative skin resurfacing treatments result in reduced side effects and downtime, they have not achieved the clinical efficacy of full-surface ablative treatments, particularly for moderate to severe rhytides. As the fractional amount of injury to skin, e.g., treatment coverage, is increased to improve efficacy, side effects and downtime may increase. With multiple treatment procedures, improvements in efficacy saturate and this ratio may worsen as a consequence of increased downtime. The ratio of clinical efficacy to side effects and downtime is therefore a useful gauge to help identify improved strategies.

The objective of fractional ablative treatments including CO<sub>2</sub> (10,600 nm), Er:YAG (2940 nm), and Er:YSGG (2790 nm) (1-4) is to realize the efficacy of full-surface ablative treatments while preserving the improved safety profile of fractional non-ablative treatments. Traditional full-surface ablative procedures provide 100% coverage

and remain the current gold standard for excellent clinical outcomes. However, high density and complete-coverage ablation correlate with an undesirable safety profile characterized by extended downtime, prolonged erythema, increased incidence of scarring, and delayed onset of hypopigmentation (5-8). In addition to the two to four months required for complete resolution of post-treatment erythema, subject downtime can last as long as two weeks due to delayed re-epithelialization of the epidermis (9,10). In contrast, fractional, non-ablative treatments leave the stratum corneum in place, resulting in a more favorable safety profile with minimal complications, milder side effects and faster re-epithelialization which contribute to decreased subject downtime. However, this modality typically uses low coverage (less than 30% in a single treatment) and is less effective than full-surface ablative procedures for moderate to severe periorbital and perioral rhytides even after multiple treatments (11,12). Fractional ablative treatments, on the other hand, result in improved clinical efficacy with typical rhytide grade improvements of 1.4 to 1.6 on the FWS (2,3,13) compared to 0.9 for fractional non-ablative methods (11) but with significantly increased side effects and downtime compared to fractional non-ablative methods. Efforts to improve efficacy by increasing depth and coverage using fractional CO<sub>2</sub> with collimated beams are also linked to prolonged recovery and other possible complications (14-16).

To achieve the high coverage and sufficient depth required for improved efficacy, fractional devices are used with multiple overlapping passes. If coverage in a single pass is high, then multiple overlapping areas will be created with this multi-pass procedure resulting in extremely high-coverage thus exceeding the rapid, safe healing capacity of the skin. If coverage in a single pass is low, then numerous passes must be delivered and excessive bulk heating or uncontrolled clustering of thermal damage columns could lead to areas of ulceration and increased side effects. Practitioners are once again faced with the tradeoff between efficacy and subject downtime as higher coverage treatments result in prolonged side effects and recovery. Somewhere among these treatment modalities lies a happy medium where near full-skin resurfacing-like clinical outcomes can be achieved with a

more favorable safety profile. We investigated a new optical device capable of delivering a unique groove pattern of injury which could potentially meet this objective of improving the ratio of clinical efficacy per unit downtime. Results from our recent clinical study, as reported at the Spring 2009 American Society for Laser Medicine and Surgery meeting (17), demonstrate the success of this Groove Optic in achieving both higher clinical efficacy (average FWS score improvement of 2.2), minimal side effects and half the subject downtime in a single treatment compared to traditional multi-pass CO<sub>2</sub> resurfacing. Initial observations and findings from this study are reported.

## Methods

**Device description:** A 2940 nm fractional Er:YAG laser (Lux2940, Palomar Medical Technologies, Inc., Burlington, MA) was equipped with the new Groove Optic which generates five parallel lines of damage spaced 1.35 mm apart with lengths of 6 mm. The damage profile was extensively characterized in (1) ex vivo Yucatan pig model and (2) in vivo human tissue using punch biopsies. Energy settings for the Groove Optic are displayed in units of millijoules per 0.1 millimeters of length (mJ/0.1 mm) which indicates the amount of energy delivered per 0.1 mm length in each of the five lines of the optic. Depending upon energy (from 2 – 5.5 mJ/0.1mm line length), pulse width settings (250  $\mu$ s, 3 ms, or 5 ms), and stacking of pulses, V-shaped grooves of injury are observed which measure from 100 to 300  $\mu$ m in width and from 150 to 500  $\mu$ m in depth (18).

**Treatment parameters:** Note that the inclusion of these parameters in this publication does not constitute a recommendation of these parameters for clinical treatment. Subjects with moderate to severe rhytides received one full-face treatment with the Groove Optic sixty minutes after the application of topical anesthetic. Treatment parameters were adjusted based on the degree of correction needed for a given treatment area. For example, dynamic, moderate to deep periorbital and perioral wrinkles received high-coverage (35-50%) treatments using higher energy settings, stacking of pulses (defined as multiple, sequential pulses on the same treatment area before moving on to another area of skin), and both short and long pulse widths. More superficial wrinkles on the rest of the face received low coverage treatments (25-35%) using lower energy settings, single non-stacked passes, and short pulse widths.

Treatments were applied in a series of passes using a single orientation of the Groove Optic with non-overlapping

pulses (Figure 1). The first treatment pass generated uni-directional lines of injury as shown in Figure 1a. Rotating the optic 90 degrees for the second pass generated a cross-like pattern (Figure 1b). The third and fourth passes were applied by rotating the optic  $\pm 45$  degrees relative to the orientation of the first pass creating two overlaid cross patterns for uniform high-coverage (Figure 1c).




Figure 1. Injury patterns generated with the Groove Optic.

**Post-treatment care:** Immediate post-treatment care included application of cool, wet compresses as needed and twice daily cleansing of the face. Subjects were instructed to keep a thin layer of occlusive ointment on their face for the first four days. In some subjects with persistent erythema and an elevated risk of hyperpigmentation, 1% hydrocortisone or hydroquinone was used prophylactically following re-epithelization of the skin. Subjects were instructed to avoid sun exposure and after two weeks, begin use of UV sun protection care.

**Assessment measures:** All side effects and skin reactions were observed immediately post-treatment, four days, seven days, fourteen days, one month and three months post-treatment. Efficacy was graded by treating clinicians and blinded-independent physicians using the Fitzpatrick Wrinkle Scale and the Diffuse Pigmentation Scale. Subject self-assessment questionnaires were used to collect data on subject satisfaction and experience.

**Results:** Treatments with the Groove Optic took between thirty and forty-five minutes and were easily tolerated using only topical anesthetic. Settings were tailored to take into account the expanse of the treatment area, amount of skin damage present and thickness of the skin. The subject shown in Figure 2 received a combination of high-coverage passes to target her deep perioral and periorbital wrinkles and standard-coverage passes for mild skin resurfacing of the rest of the face. High-coverage (40%) was achieved with energy settings of 5.5 mJ/0.1 mm and double-stacked passes. Standard-coverage (30%) was achieved with energy settings of 5.5 mJ/0.1 mm and short-pulse single non-stacked passes. The time course of her skin reactions and side effects are shown in

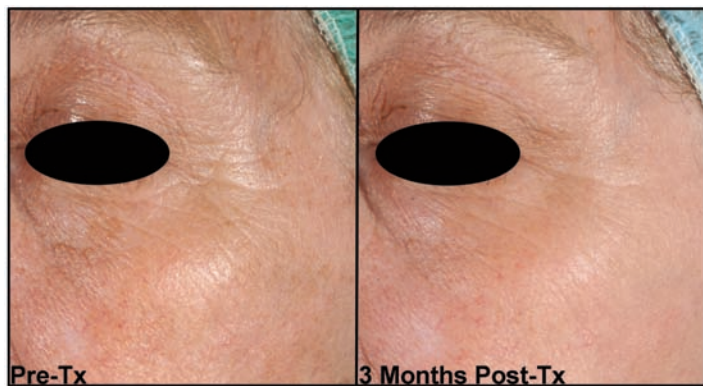
Figure 2 and were typical for the procedure. Immediately post-treatment, the pattern from the four-pass, two cross technique was clearly visible in all of the treated areas. The high visibility of this pattern underscores the ease with which the practitioner can accurately rotate and reposition the optic between passes and also underscores the high degree of uniformity which can be achieved. Post-treatment erythema and swelling were completely resolved by two weeks. Clearance of dyspigmentation was also evident at this time. By three months post-treatment, significant improvements in the subjects' perioral and periorbital wrinkles were observed due to the deposition of new collagen. This subject was very satisfied with her results and received numerous unsolicited comments from others on the improvements in her skin.

The subject shown in Figures 3 and 4 is an example of someone who received a range of treatment settings on her face to deliver customized results based on the degree of damage present in each region of her face. Figures 3 and 4 show

dramatic improvements in periorbital and perioral wrinkles following high-coverage treatment using energy settings of 5.5 mJ/0.1mm with stacked pulses for the first two passes and non-stacked pulses for the two cross passes generating an overall coverage of 45 – 50%. The moderately deep periorbital rhytides visible prior to treatment with the Groove Optic appear significantly diminished at three months post-treatment (Figure 3). Careful examination of high-resolution images, as well as face to face evaluations by the treating physician, confirmed these improvements could not be attributed to any residual localized edema, suggesting that, in fact, the underlying wrinkle infrastructure had been successfully disrupted and potentially enhanced via neocollagenesis. Significant improvements in the texture and tone of the skin are also evident in the three month follow-up image (Figure 4), a benefit we attribute to the high coverage treatment.

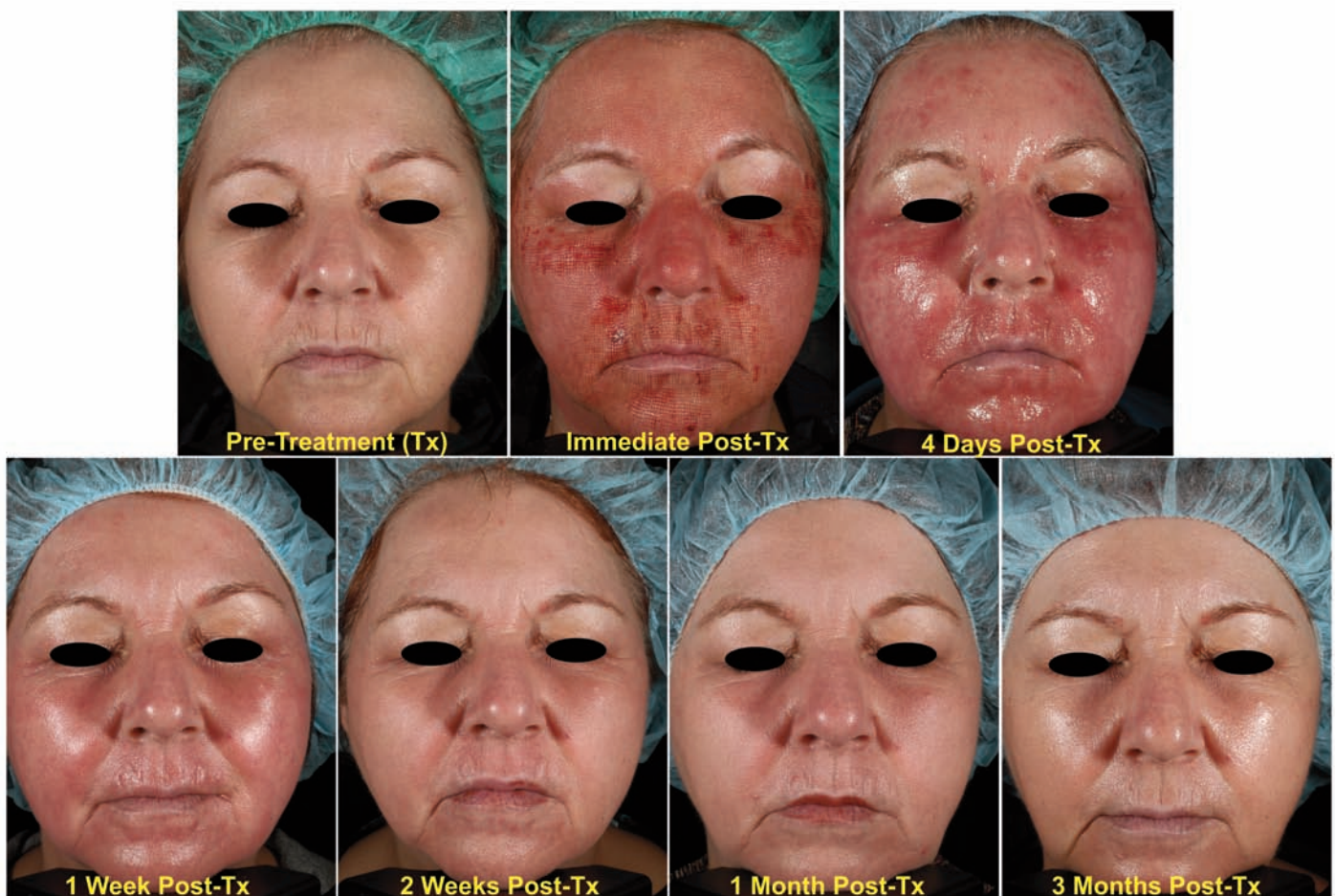

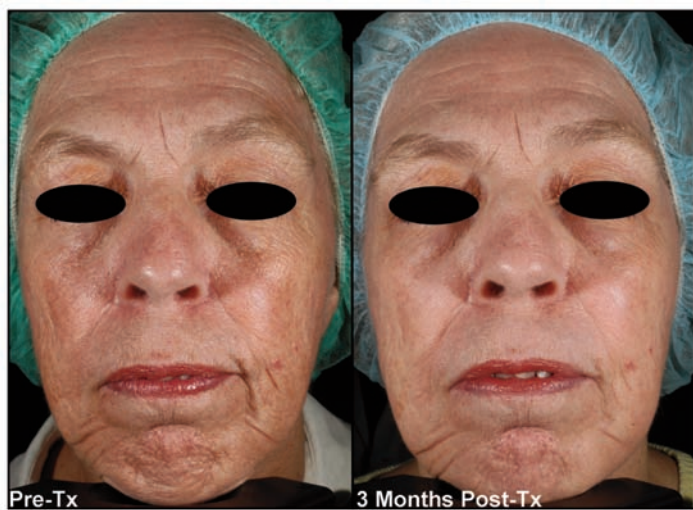Figure 2. Healing timecourse following treatment with the Groove Optic.



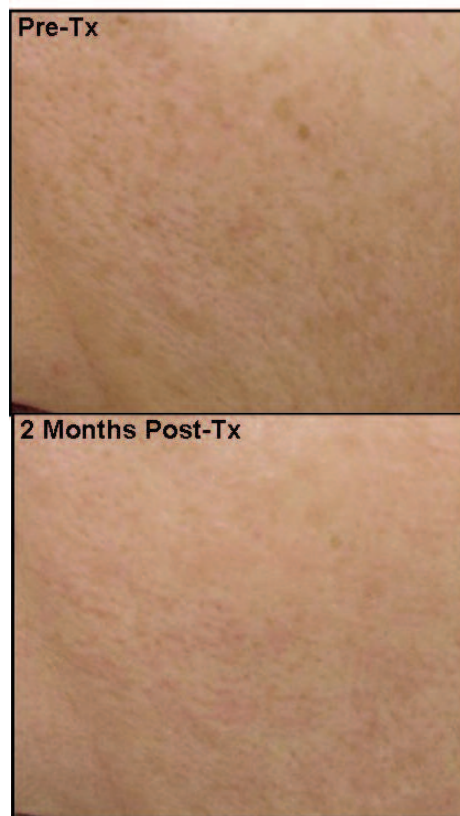**Figure 3.** High-coverage treatment yields significant improvements in periorbital wrinkles.

Full-face photos (Figure 4) show the combined effects of tailored, region-specific, high-coverage treatment. The perioral region received the same high coverage (45-50%) treatment as periorbital wrinkles (see parameters above) while the rest of the face received two to four passes of non-stacked pulses for approximately 30% total coverage. This frontal view highlights the remarkable, global improvement in widespread dyspigmentation following a single treatment with the Groove Optic. Irregularities present in the skin, such as uneven texture and tone, are substantially reduced and the translucency of the skin is more evident. All contribute to the more youthful glowing appearance of the skin.



**Figure 4.** Region-customized treatment for optimal improvements in wrinkles and dyspigmentation.

Figure 5 highlights the typical degree of improvement we observed in dyspigmentation, skin texture and tone in our subjects. Prior to Groove Optic treatment, the subject's cheek was characterized by noticeable foci of dyspigmentation as well as irregularities in the texture and tone of the skin. By only two months post-treatment, the dyspigmentation was remarkably reduced or absent and both the texture and tone of the skin appeared evened out.



**Figure 5.** Evening out of skin tone and texture occurs as early as two months post-treatment.

Our experiences using the Groove Optic, support the treatment settings shown in Table 1 for targeting of moderate to deep wrinkles and skin resurfacing. For wrinkles in the perioral and periorbital zones: settings of 5.5 mJ/0.1 mm with a 250  $\mu$ s pulse width for the first two passes. These passes should be “double-stacked” meaning that the passes are delivered sequentially with the handpiece held in place for two pulses. Between the first and second “double-stacked” passes, the handpiece should be rotated 90 degrees to form a single cross pattern. The third and fourth passes are performed either at 5.5 mJ/0.1 mm with a 250  $\mu$ s pulse width, or one pass with those settings followed 100 ms later by a second pass at 4.5 mJ/0.1 mm with a 3 ms pulse width (dual-pulse mode). The third and fourth passes should not be stacked. Prior to beginning the third pass, the handpiece should be rotated +45 degrees relative to the orientation of the first pass and -45° for the fourth pass to generate a second overlaid cross pattern.

The settings for skin resurfacing are milder with no stacking of passes. The first and second passes should be performed at 5 mJ/0.1 mm with a 250  $\mu$ s pulse width using the cross orientation and the third and fourth passes should be applied using the same settings with  $\pm$ 45 degree rotation for the overlaid cross patterns. Deep facial wrinkles can be addressed with double-stacking of the first two passes.






Groove Optic Lux2940	Wrinkle Target Treatment Areas (except inside bony orbit)			Skin Resurfacing for Rest of Face (including inside bony orbit)		
	Setting	Depth	Coverage	Setting	Depth	Coverage
Lux2940 Groove Optic Setting Pattern 	5.5 mJ/0.1 mm 250 µs pulse width Double stacked first & second pass 	225 µm	24%	5.5 mJ/0.1 mm 250 µs pulse width first & second pass 	140 µm	17%
	5.5 mJ/0.1 mm 250 µs pulse width <i>Or</i> *5.5 mJ/0.1 mm 250 µs pulse width + 5.5 mJ/0.1 mm 3 ms pulse width third & fourth pass (dual-pulse mode) 	140 or 185 µm	14-17%	5.5 mJ/0.1 mm 250 µs pulse width third & fourth pass 	140 µm	14%
Total Coverage: 35-37%			Total Coverage: 29%			

Table 1. Groove Optic treatment settings for wrinkle reduction and skin rejuvenation.

\* Use caution when treating darker skin types, e.g., Fitzpatrick skin types of dark III, IV and V with dual-pulse mode to avoid risk of hyperpigmentation. Preferable settings for these skin types are: 5.5 mJ/0.1 mm at 250 µs pulse width. Refer to Operator's Manual for complete set of treatment guidelines.

Overall, as presented at the Spring 2009 ASLMS meeting, we found significant clinical benefits following treatment with the Groove Optic for skin resurfacing of photodamaged skin. Using objective assessment measures (blinded-investigator review, n = 17), our results demonstrated significant improvements in FWS score and dyspigmentation score with an average score improvement greater than two for both scales at three months post-treatment (17). Use of our high-coverage, low-pass technique achieved effective and consistent results for deep perioral and periorbital wrinkles. This technique resulted in high rates of subject satisfaction and willingness to recommend to others. Despite the high-coverage, the healing capacity of the skin was preserved as demonstrated by the minimal downtime (average of four days) and rapid resolution of side effects (erythema typically resolved by two to three weeks). Additional feedback collected from subjects at the end of the study was overwhelmingly positive as subjects reported their skin “felt tighter”, “looked smoother”, “wrinkles were reduced” and their skin had a “more natural color and even skin tone”.

## Discussion

The substantial improvements observed in moderate to severe rhytides and in dyschromia following a single high-coverage treatment with the Groove Optic occurred without a corresponding increase in side effects or downtime. This strategy, therefore, significantly improves the ratio of clinical benefits to side effects and downtime and as such, represents a major advance in skin resurfacing and wrinkle treatment.

The faster improved healing following Er:YAG 2940 nm treatments in comparison to CO<sub>2</sub> 10,600 nm treatment is well-documented following traditional full-surface procedures (10). Regarding wrinkle improvement, this study showed a 38-50% improvement in outcome for FWS scores (reductions of 2.2) when compared to FWS outcomes reported for other fractional ablative treatments (reductions of 1.4-1.6) (2,3,13).

We attribute these improved outcomes to the (a) unique fractional injury pattern, (b) uniformity and (c) high coverage, up to 50%, using the new Groove Optic with the fractional Er:YAG 2940 nm laser. The unique injury pattern, in comparison to vertical columns of damage, is generated by the Groove Optic using multiple passes of controlled orientation. The resulting pattern of injury may not only better disrupt the intrinsic memory of wrinkles, but also may lead to neocollagenesis. The continuity and length of these channels of new collagen could provide better tightening and structure to the skin contributing to the improvement in reduction of wrinkles.

The high visibility of the groove pattern as it appears on the skin surface enables the practitioner to carefully track passes to ensure evenness and uniformity of treatment and most importantly, to achieve high-coverage without excessive clustering or overlap. Even with increased depths from stacking of pulses, the narrow lines of damage heal with rapid re-epithelialization and are free of complications. For example, in these subjects, coverages of 45-50% were applied with downtimes of four to five days and no lingering side-effects. This is a distinct advantage compared to fractional CO<sub>2</sub> where recent reports of long term side effects and scarring have been reported (14-16).

### Summary & Conclusion

Groove patterns of fractional ablation were used for skin resurfacing using a unique injury pattern with high uniformity and high coverage. Single treatments resulted in consistent and substantial reductions in wrinkles and dyschromia with excellent overall enhancement in the appearance of skin without corresponding increased side effects and downtime. This strategy therefore significantly improves the ratio of clinical benefits to side effects and downtime, and as such, represents a major advance in fractional skin resurfacing technology.

### References

1. Hantash BM, Bedi VP, Kapadia B, Rahman Z, Jiang K, Tanner H, Chan KF, Zachary CB. In vivo histological evaluation of a novel ablative fractional resurfacing device. *Lasers Surg Med* 2007; 39(2):96-107.
2. Berlin AL, Hussain M, Phelps R, Goldberg DJ. A prospective study of fractional scanned nonsequential carbon dioxide laser resurfacing: a clinical and histopathologic evaluation. *Dermatol Surg* 2009; 35(2):222-228.
3. Dierickx CC, Khatri KA, Tannous ZS, Childs JJ, Cohen RH, Erofeev A, Tabatadze D, Yaroslavsky IV,

Altshuler GB. Micro-fractional ablative skin resurfacing with two novel erbium laser systems. *Lasers Surg Med* 2008; 40(2):113-123.

4. Ross EV, Swann M, Soon S, Izadpanah A, Barnette D, Davenport S. Full-face treatments with the 2790-nm erbium:YSGG laser system. *J Drugs Dermatol* 2009; 8(3):248-252.
5. Nanni CA, Alster TS. Complications of carbon dioxide laser resurfacing. An evaluation of 500 patients. *Dermatol Surg* 1998; 24(3):315-320.
6. Bernstein LJ, Kauvar AN, Grossman MC, Geronemus RG. The short- and long-term side effects of carbon dioxide laser resurfacing. *Dermatol Surg* 1997; 23(7):519-525.
7. Zachary CB. Modulating the Er:YAG laser. *Lasers Surg Med* 2000; 26(2):223-226.
8. Ward PD, Baker SR. Long-term results of carbon dioxide laser resurfacing of the face. *Arch Facial Plast Surg* 2008; 10(4):238-243; discussion 244-235.
9. Ratner D, Tse Y, Marchell N, Goldman MP, Fitzpatrick RE, Fader DJ. Cutaneous laser resurfacing. *J Am Acad Dermatol* 1999; 41(3 Pt 1):365-389; quiz 390-362.
10. Khatri KA, Ross V, Grevelink JM, Magro CM, Anderson RR. Comparison of erbium:YAG and carbon dioxide lasers in resurfacing of facial rhytides. *Arch Dermatol* 1999; 135(4):391-397.
11. Manstein D, Herron GS, Sink RK, Tanner H, Anderson RR. Fractional photothermolysis: a new concept for cutaneous remodeling using microscopic patterns of thermal injury. *Lasers Surg Med* 2004; 34(5):426-438.
12. Christiansen K, Bjerring P. Low density, non-ablative fractional CO<sub>2</sub> laser rejuvenation. *Lasers Surg Med* 2008; 40(7):454-460.
13. Rahman Z, MacFalls H, Jiang K, Chan KF, Kelly K, Tournas J, Stumpp OF, Bedi V, Zachary C. Fractional deep dermal ablation induces tissue tightening. *Lasers Surg Med* 2009; 41(2):78-86.
14. Ross RB, Spencer J. Scarring and persistent erythema after fractionated ablative CO<sub>2</sub> laser resurfacing. *J Drugs Dermatol* 2008; 7(11):1072-1073.
15. Fife DJ, Fitzpatrick RE, Zachary CB. Complications of fractional CO<sub>2</sub> laser resurfacing: four cases. *Lasers Surg Med* 2009; 41(3):179-184.
16. Avram MM, Tope WD, Yu T, Szachowicz E, Nelson JS. Hypertrophic scarring of the neck following ablative fractional carbon dioxide laser resurfacing. *Lasers Surg Med* 2009; 41(3):185-188.
17. Doherty S, Seckel BR. Advantages of a groove pattern of micro-fractional ablation for facial skin resurfacing. *Lasers Surg Med* 2009; 41(S21):84.